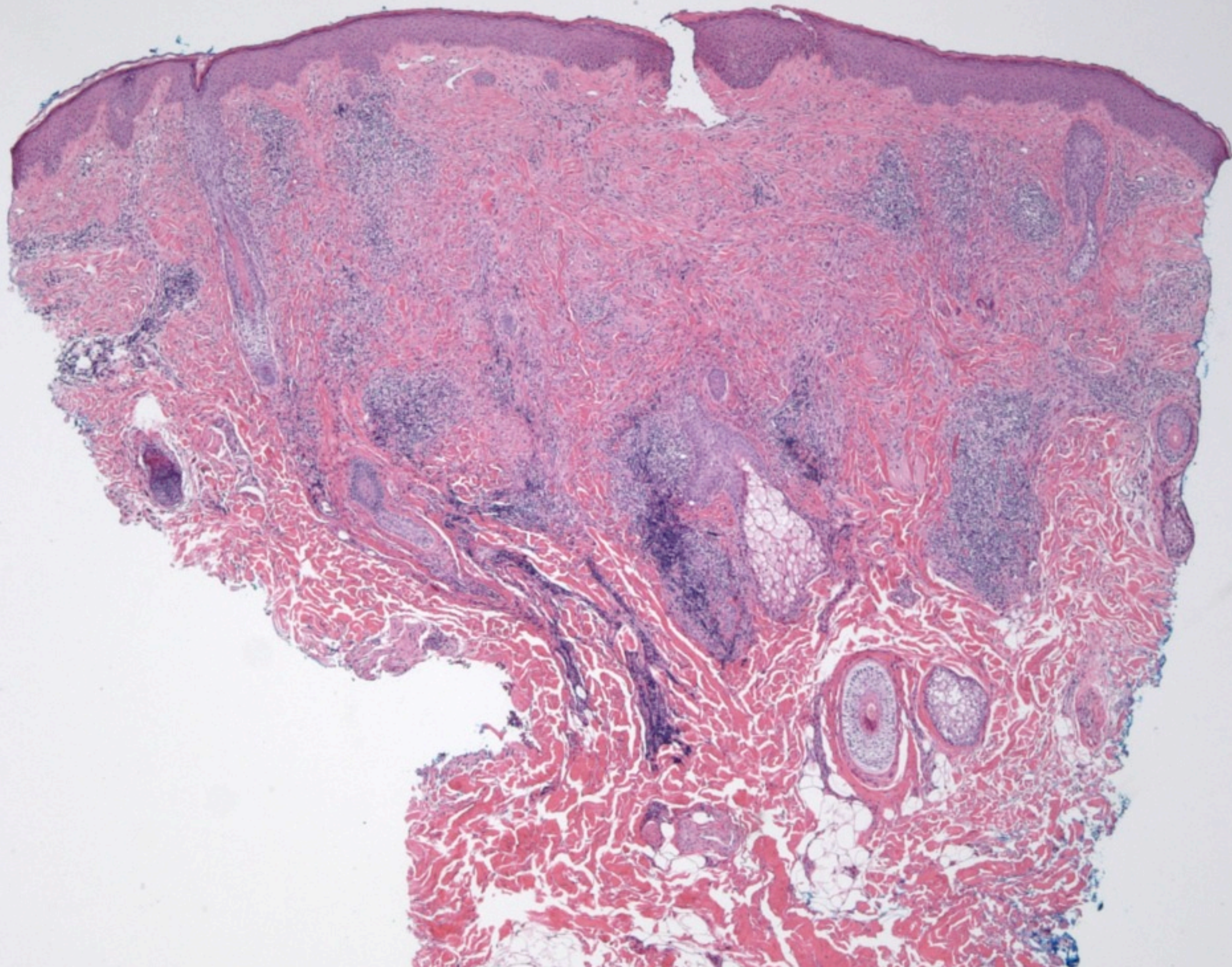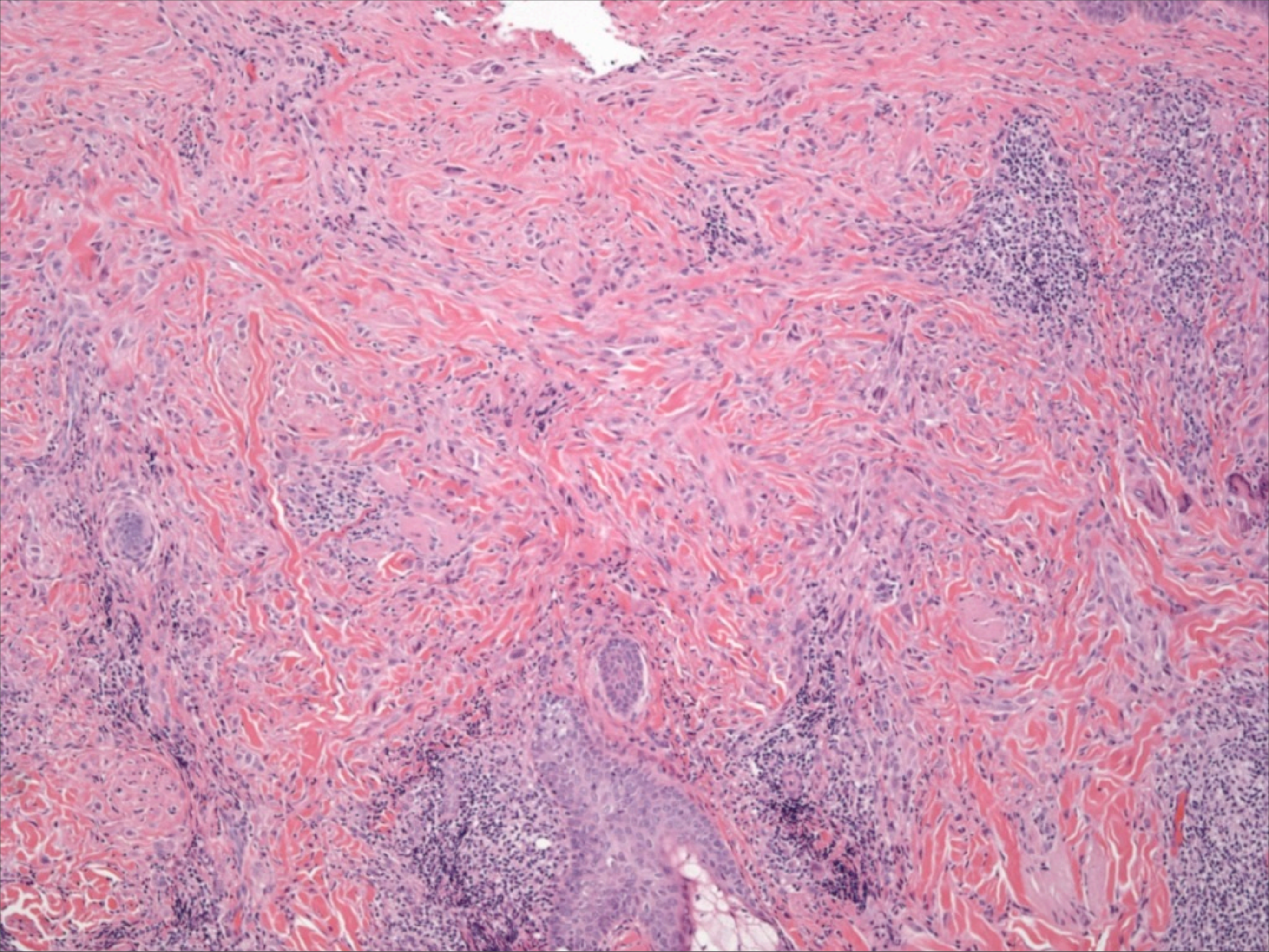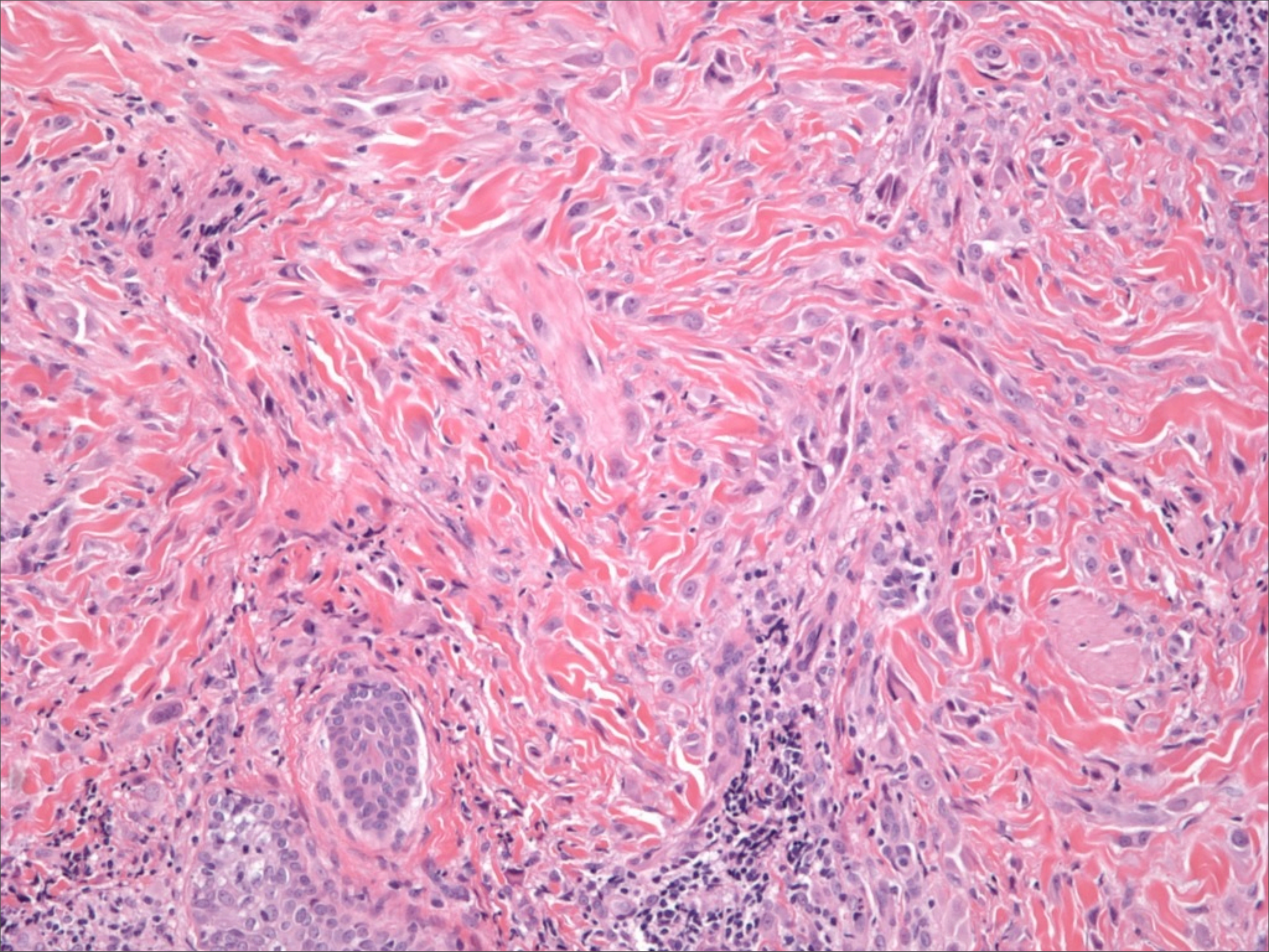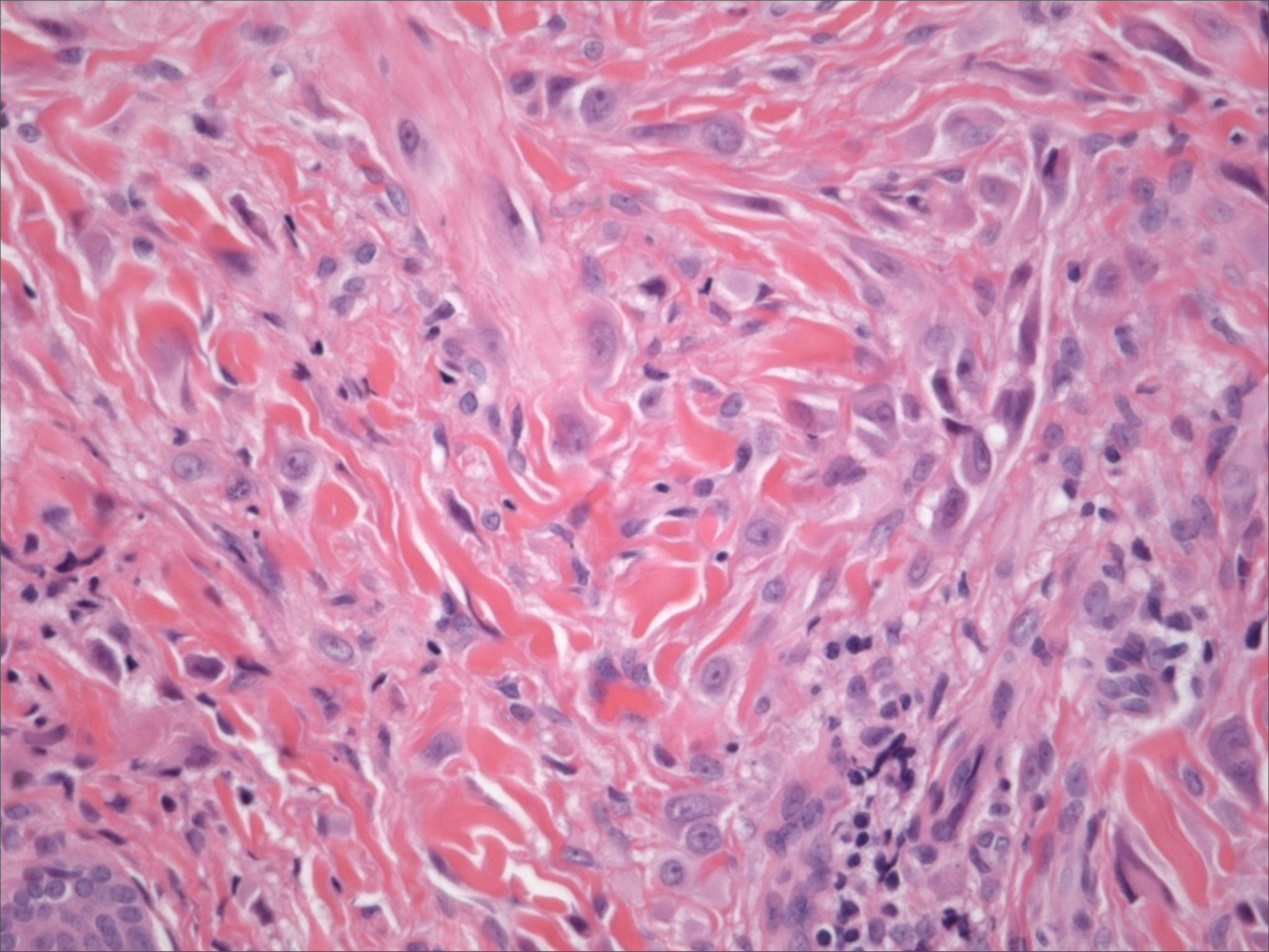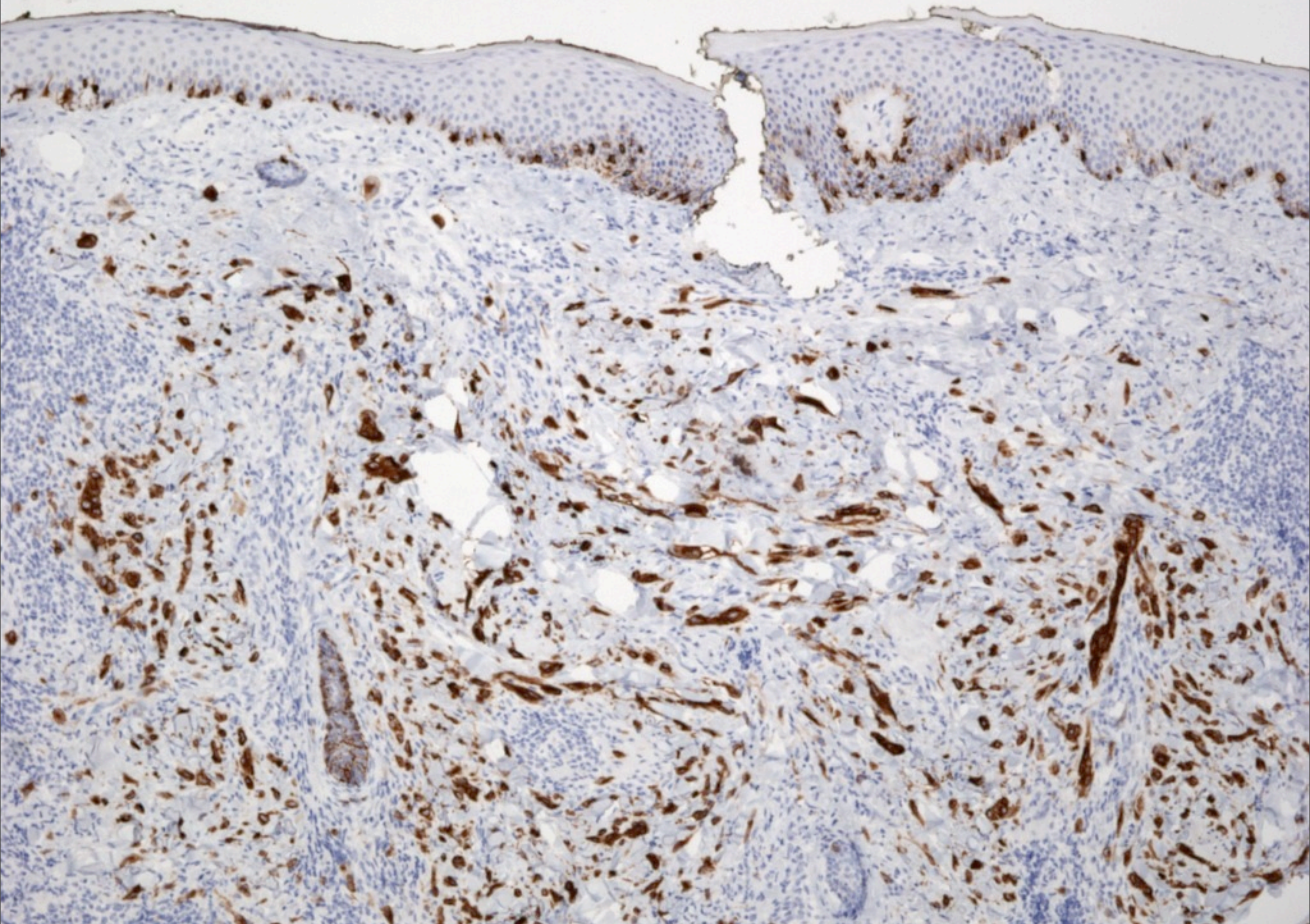
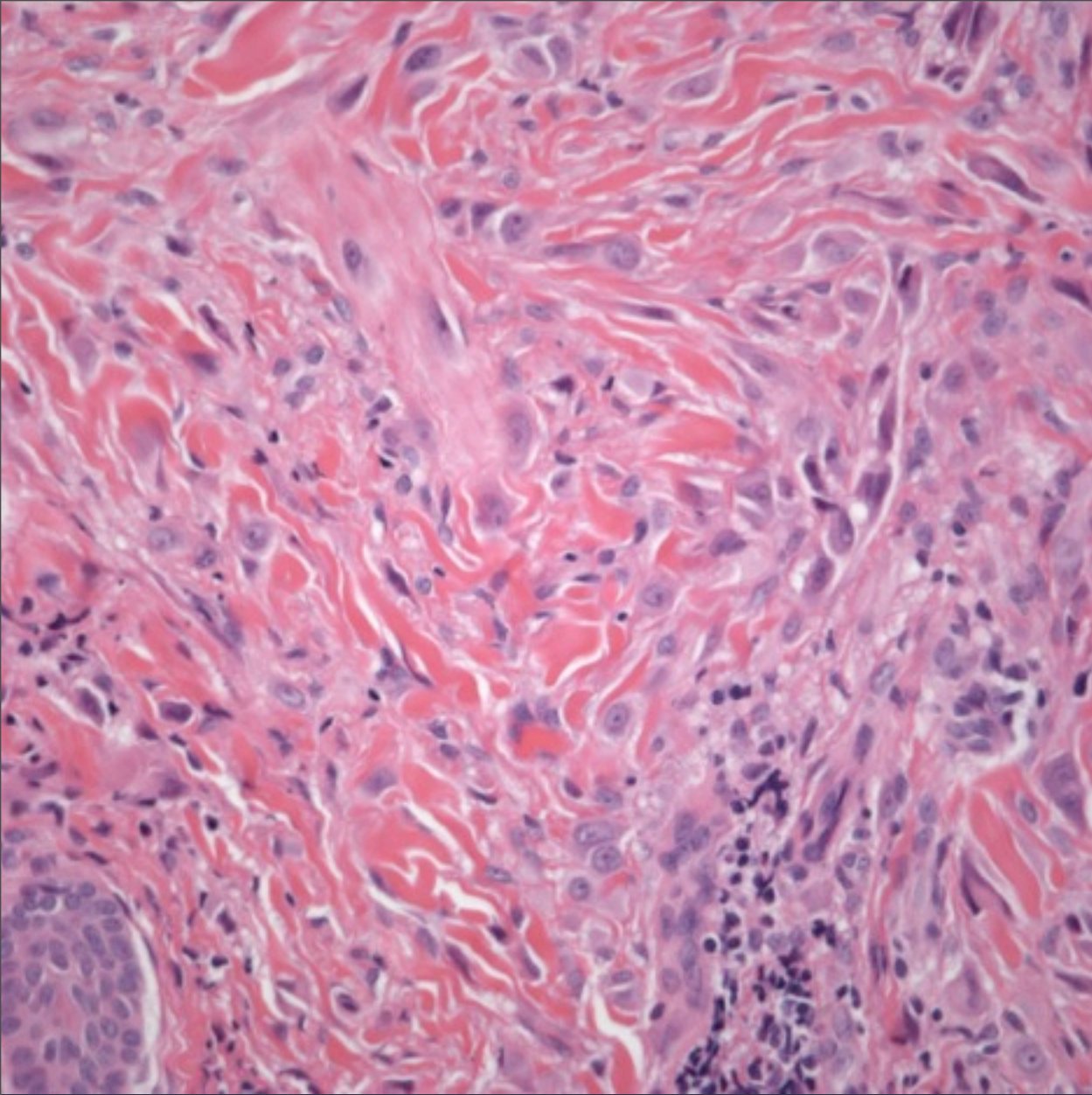


Melan A



Desmoplastic Nevus



Epithelioid and spindled melanocytes localized in dermis

No atypical mitotic figures or deep mitotic figures

Minimal to absent melanin pigment

May need to confirm with IHC